

Continued eruption of maxillary incisors and first molars in girls from 9 to 25 years, studied by the implant method

Haluk Iseri* and Beni Solow**

Departments of Orthodontics, School of Dentistry, *University of Ankara, Turkey, and

**University of Copenhagen, Denmark

SUMMARY The aim of this study was to describe the average and individual patterns of continued eruption of the maxillary incisors and first molars in a longitudinal sample of girls. The sample comprised 14 series of lateral cephalometric films of girls, obtained from the archives of the implant study of Björk (1968). All subjects had bilateral posterior maxillary implants and one or two anterior maxillary implants. Subjects with craniofacial anomalies were excluded. The sample represented various types of malocclusions, but records during periods of orthodontic treatment were excluded from the calculation of average data and average curves. The final sample comprised 147 radiographs in the age range 9–25 years. Data were debugged by comprehensive numerical and graphical procedures.

The average cumulative continued eruption from 9–25 years of age was 6 mm downwards and 2.5 mm forwards for the upper incisors, and 8 mm downwards and 3 mm forwards for the upper first molars. This resulted in an average reduction of the occlusal plane inclination (OLs/IPLs) of 4.5 degrees from 9–16 years.

Attention is drawn to the fact that due to the continued eruption of the natural teeth, the use of osseointegrated implants with artificial teeth should not be recommended in childhood, adolescence, and early adulthood, unless special provision is made for later revision or replacement of the artificial teeth to compensate for the lack of continued eruption of such implants.

Introduction

In humans, the teeth, after full emergence, exhibit a continued eruption, accompanying the growth in height of the alveolar processes until the termination of facial growth, and probably, at a much reduced rate, for a considerable period thereafter (Carlsson, 1944; Burke, 1954; Baer, 1956; Tallgren, 1957; Murphy, 1959; Schumacher and El Hadary, 1960; Thompson and Kendrick, 1964; Siersbæk-Nielsen, 1971; Björk and Skieller, 1972; Ainamo and Talari, 1976a, b; Forsberg, 1979; Forsberg *et al.*, 1991; Sarnäs and Solow, 1980; Mazeland, 1980; Behrents, 1985a, b; Tallgren and Solow, 1991). Knowledge about this continued eruption is essential for understanding facial growth as well as in orthodontic treatment planning. Moreover, the interest in the amount and duration of continued eruption of the teeth has taken a new turn in recent years with the introduction of the technique of osseointegrated

implants inserted directly into the alveolar processes (Brånemark *et al.*, 1977). Such implants have been used for orthodontic anchorage (Gray *et al.*, 1983; Turley *et al.*, 1988; Ödman *et al.*, 1988, 1994; Roberts *et al.*, 1989; Haanaes *et al.*, 1991), and experimental studies have confirmed that osseointegrated implants behave like ankylosed teeth, and thus do not follow the continued eruption of the adjacent natural teeth during growth (Ödman *et al.*, 1991; Thilander *et al.*, 1992). Artificial teeth on osseointegrated implants have also been used as a supplement to orthodontic treatment procedures in orthodontic patients with missing teeth (Ödman *et al.*, 1988, Thilander *et al.*, 1994). Since ankylosed artificial teeth on osseointegrated implants will not follow the continued eruption of neighbouring teeth it is of particular importance to determine the amount of continued eruption of the teeth in adolescence and early adulthood.

The precise determination of the direction and rate of continued eruption of the teeth requires

the use of stable reference structures in the jaws. Since stable natural reference structures are particularly difficult to determine in the maxilla, the best method for the systematic study of the continued eruption of the maxillary teeth is that based on metallic implants inserted in the jaws, as developed by Björk (1955, 1968). Siersbæk-Nielsen (1971) by this method reported the individual rates of eruption of the central incisors in eight boys in the years around puberty. Björk and Skieller in a series of implant studies (1972, 1977, 1983) described various features of the process of continued eruption.

The studies based on the implant method have reported data mainly for males or for both sexes pooled. The purpose of this study was to describe the continued eruption of the maxillary incisors and molars in a longitudinal sample of girls, analysed by the method of metallic implants.

Subjects and methods

The material was obtained from the archives of the implant study of Björk (1968), and com-

prised annual lateral cephalometric films of 14 girls in the age range 9–25 years. The criteria for selection were the presence of bilateral posterior maxillary implants and one or two anterior maxillary implants. The sample represented various types of malocclusions. Four subjects received orthodontic treatment before or after the observation period, while eight subjects were treated between periods of observation. Two subjects received no orthodontic treatment. Records during periods of orthodontic treatment and retention were excluded from the calculations of average data and average curves. The final sample comprised 147 radiographs in the age range 9–25 years (Fig. 1).

Radiographic procedures

The radiographs were taken in a Lumex type B cephalometer (Björk, 1968) with fixed focus-to-midsagittal plane and midsagittal plane-to-film distances of 180 and 10 cm. This ensures a constant enlargement of 5.6 per cent of the median plane, and thus makes direct superimposition of sequential films from the same sub-

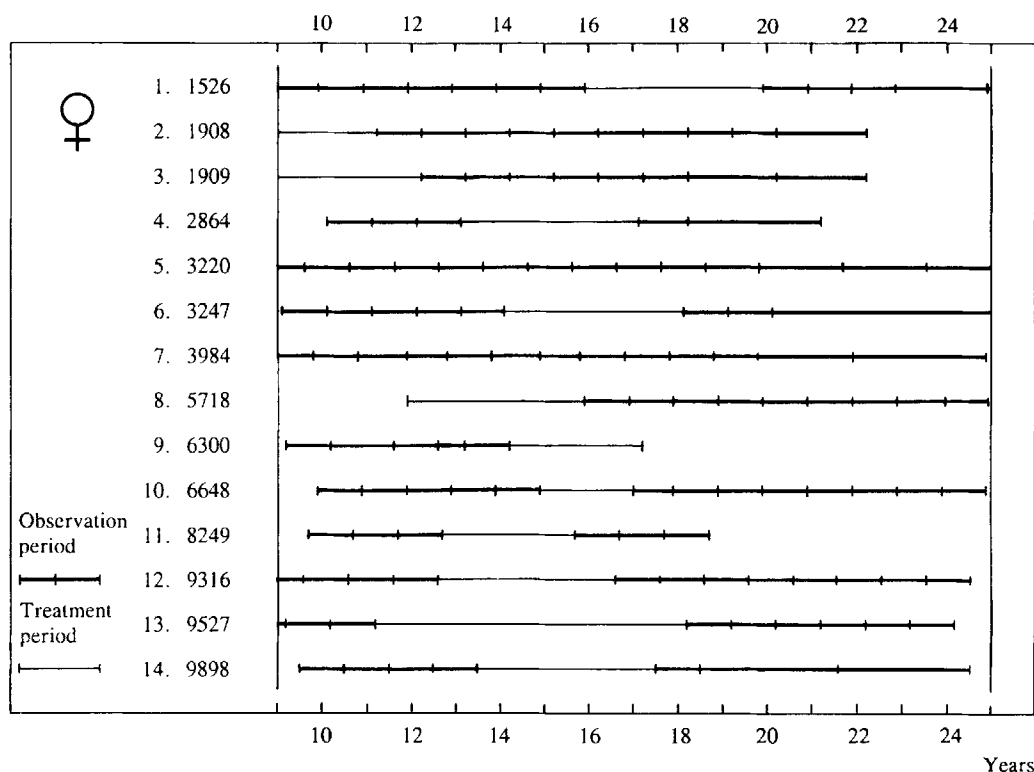


Figure 1 Survey of sample. Vertical bars indicate cephalometric records analysed in the present study.

ject possible. Data were not corrected for radiographic enlargement. Intensifying screens and a movable grid were used to reduce exposure dose and scattered radiation on the films. An aluminium wedge between the subject and the film was used to improve soft tissue contrast.

Reference points

One anterior and one posterior implant point were determined from the radiographic images of the bilateral sets of implants. Implant points, fiducial points, and 14 anatomical reference points were marked with a soft, finely-pointed pencil directly on each film and were digitized on a Summagraphics Supergrid^R digitizer (Summagraphics^R Corp., 35 Brentwood Ave., Fairfield, Connecticut 06430, USA), as described by Iseri and Solow (1990, 1995). The points used in the present study are shown in

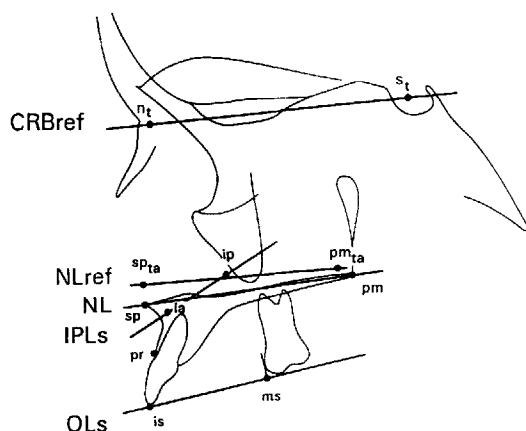


Figure 2 Reference points and lines on the cephalometric films. The tracing represents a late film in a series. Fiducial points n_t and s_t ; reference points nasion and sella on first film, transferred by superimposition on stable structures in anterior cranial base. CRBref: cranial base reference line through n_t and s_t . NL: nasal line (palatal plane) through reference points sp (spinal point, ANS) and pm (pterygo-maxillare, PNS). The sp and pm points of the first film of each subject served as fiducial points for the superimpositions and were transferred to the other films. NLref: maxillary reference line through transferred fiducial points sp_{ta} and pm_{ta} determined by superimposition on maxillary implant line IPLs through anterior (ia) and posterior (ip) maxillary implant points, registered on anterior implant point. This superimposition is used for assessment of the continued eruption of the incisors (is) and the relocation of point pr . Fiducial points sp_{ip} and pm_{ip} , determined by superimposition on IPLs but registered on posterior implant point, are not shown. This superimposition was used for assessment of the continued eruption of the upper molars (ms). OLs: upper occlusal plane through is and ms .

Figure 2. Data were debugged by comprehensive numerical and graphical procedures (Iseri and Solow, 1995). The variables were calculated from the co-ordinates and the statistical analysis was carried out by the SAS statistical program package (Helwig and Council, 1979).

Terminology

Two terms were defined in order to describe the continued eruptive movements of the maxillary incisors and first molars, continued eruption and translocation (Fig. 3). The continued eruption of a maxillary tooth was defined as the displacement of the tooth in relation to the maxillary base. This was assessed by superimposition on the maxillary implants. The translocation of a maxillary tooth was defined as the combined effect of the growth displacement of

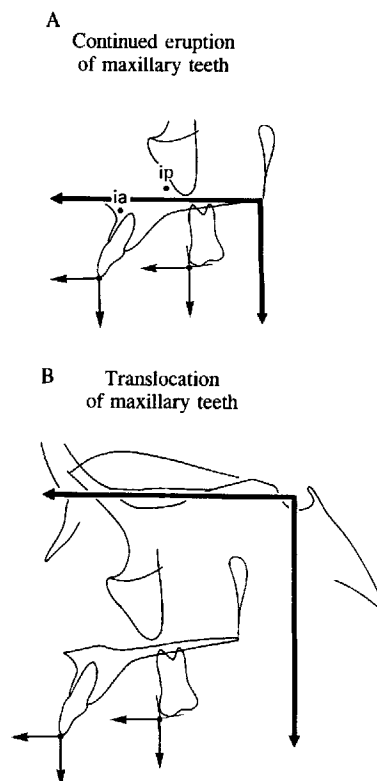


Figure 3 Definitions of continued eruption and translocation. A: Continued eruption of a maxillary tooth is defined as the displacement of the tooth in relation to the maxillary base (NLref). B: translocation is defined as the combined effect of the growth displacement of the maxillary body and the continued eruption of a maxillary tooth or the relocation of a maxillary osseous reference point. The translocation is assessed in relation to the cranial base (CRBref).

the maxillary body and the eruption of the tooth. Similarly, the translocation of the reference point prosthion was defined as the combined effect of the growth displacement of the maxillary body and the relocation of prosthion. The translocation was assessed by superimposition on stable structures in the anterior cranial base.

Superimpositions

The assessment of continued eruption of the maxillary incisors and molars and the relocation of point pr was based on the method of superimposition on maxillary implants. All films from each subject were superimposed sequentially on the implant line of the first film. The sp and pm points of the first film of each subject served as fiducial points for the superimpositions. The reference line through the transferred fiducial points was termed NLref. Two maxillary superimpositions were made for each film (Iseri and Solow, 1995), one registered on the anterior implant point, ia, and one registered on the posterior implant point ip, (Fig. 2). For assessment of the translocation, superimposition was made on stable bony structures in the anterior cranial base (Björk and Skieller, 1983, Iseri and Solow, 1990). The nasion and sella points of the first film served as fiducial points which were transferred to the subsequent films of a series. The reference line through these points was termed CRBref.

Growth tracks and paths of continued eruption and translocation

The growth tracks and paths of continued eruption and translocation were obtained by cumulating the annual average growth changes for the 15 1-year age-interval groups (Table 1). The age-interval groups were defined by means of the interval midpoints. Thus the first age-interval group, '10 years', comprised those 1-year observation periods that had a midpoint in the range 9.5–10.49 years. For details regarding the age grouping, the reader is referred to Iseri and Solow (1990). The curve point at the lower class limit of the first interval, 9.5 years, was set to zero, and the increments were plotted in the upper class limits. For each subject, periods of treatment and retention were automatically excluded from the calculations of the annual average growth changes. Intervals larger than 1 year due to missing observations were

Table 1 Survey of age-interval groups.

Midpoint group	n	Midpoint age (years)		
		Mean	Minimum	Maximum
9	5	9.11	8.71	9.36
10	10	10.05	9.63	10.41
11	11	11.03	10.58	11.41
12	11	12.04	11.58	12.40
13	10	12.97	12.58	13.41
14	8	13.99	13.64	14.41
15	5	15.04	14.69	15.37
16	6	16.07	15.71	16.41
17	8	17.12	16.72	17.44
18	10	18.08	17.63	18.41
19	8	19.06	18.62	19.41
20	7	20.05	19.63	20.42
21	5	21.19	20.70	21.41
22	5	22.19	21.70	22.42
23	4	23.16	22.71	23.44
24	4	24.16	23.70	24.46

also excluded from the calculations. After these exclusions, the number of observations per age group ranged from four to 11.

Forward changes of the x co-ordinates and downward changes of the y co-ordinates were considered positive. The angle IPLs/OLs was defined so that a forward rotation of the occlusal line became negative.

Velocity curves

The velocity curves for the continued eruption and translocation of the teeth represent the means of the individual annual velocities of those subjects that were included in each age-interval group (Table 1). The annual amounts of total positional change (is tot., ms tot., s-is, s-ms) were calculated from the annual changes of the x and y co-ordinates, and thus were always considered positive. The velocities were calculated as (positional change)/(period of observation) since the annual periods of observation sometimes fluctuated by a few days.

Method errors

For assessment of method errors, $s(i)$, all points were removed from the two films representing the year of peak growth in all 14 girls and were subsequently marked again. No systematic errors were found between the two assessments of growth changes. The method errors ranged from 0.2–0.3 mm for the linear dimensions, and were around 0.7 degrees for the angular dimensions.

Continued eruption of the maxillary central incisors and first molars

Translocation of the maxillary central incisors and first molars

lary central incisors from 9–25 years of age was approximately 9.5 mm downwards and 6.5 mm forwards. The translocation of the ms point was on average about 12.5 mm downwards and 7.5 mm forwards during the same period.

Relocation and translocation of reference point prosthion

Registered on the anterior implant point, the pr point showed an average cumulative relocation of about 6 mm downwards and 2 mm forwards due to surface remodelling (Fig. 4). With the additional growth displacement of the maxilla in relation to the anterior cranial base, the pr point on average was translocated 9.5 mm downwards and 6 mm forwards in relation to the anterior cranial base (Fig. 5).

The occlusal plane

Due to the differential average continued eruption of the incisors and molars, there was a cumulative mean reduction in the inclination of the upper occlusal plane in relation to the implant line (IPLs/OLs) of 4.5 degrees from

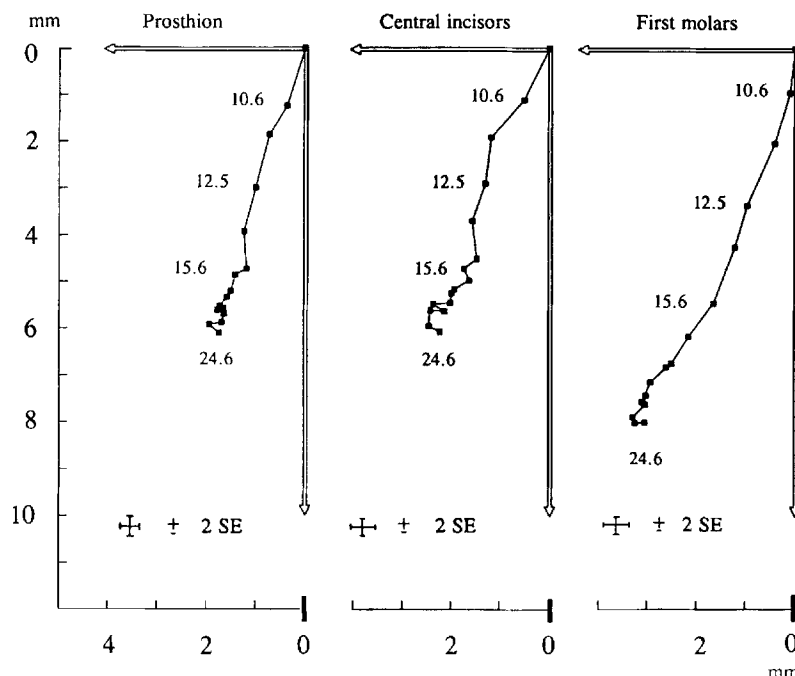


Figure 4 *Continued eruption and relocation.* Average paths of continued eruption of maxillary incisors (is) and first molars (ms), and average path of relocation of the reference point prosthion (pr). The horizontal axes of the diagrams represent NLref; the numbers on the curves indicate the mean ages. Superimposition on IPLs, registered on ia for is and pr, and on ip for ms. The initial locations of the reference points pr, is, and ms were arbitrarily set to zero on the horizontal and vertical axes in this and the subsequent illustrations.

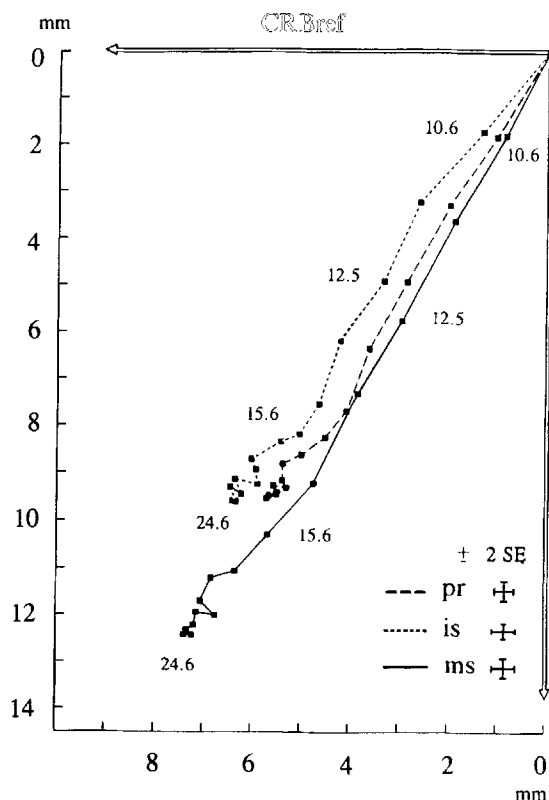


Figure 5 Translocation. Average paths of translocation of maxillary incisors (is), maxillary first molars (ms), and pr in relation to the cranial base. The horizontal axis of the diagram represents CRBref; the numbers on the curves indicate the mean ages. In this diagram, the points of origin of the three curves have been superimposed to facilitate comparison.

10–16 years of age, after which time no systematic change was observed. In relation to the anterior cranial base, CRBref, the inclination was reduced by about 5 degrees, and in relation to the palatal plane, NL, by about 6.5 degrees (Fig. 6).

Velocity of eruption and translocation

The velocity curves for the eruption and translocation of is and ms are given in Figures 7 and 8. For the maxillary central incisors, the average velocities decrease gradually from 10 years of age to about 18. For the maxillary first molars, the curves peak at the age of 12 years (Translocation: 2.5 mm/year, eruption: 1.5 mm/year), and show a postpubertal decrease in velocity until the age of 17, followed by a gradual slight decrease to a level of about 0.1–0.2 mm/year

which corresponds to the method errors for these variables.

Relation to facial development

The variability in amount and direction of continued eruption of incisors and molars is large, but obviously this variability is related to the direction of general facial development in each subject. This is illustrated by two untreated cases with extreme facial development:

Case 3984 (Figs. 9, 10) is an untreated forward mandibular rotation case with the fulcrum of rotation at the incisors. The amount of vertical eruption was considerably less for the incisors than for the molars, resulting in a smaller inclination of the upper occlusal plane in relation to the implant line. The direction of eruption was generally downwards and forwards for both incisors and molars. At the age of 12 years 10 months the eruption of incisors and molars changed in a forward direction, probably due to the termination of maxillary sutural growth and the resulting compensatory dento-alveolar adaptation to the continued forward growth of the mandible.

Case 3220 (Figs. 11, 12) is an untreated backward mandibular rotation case, with an increase in anterior lower facial height. Despite the backward rotation, the vertical amount of continued eruption of the molars was somewhat larger than that of the incisors. In this case an anterior open bite developed, indicating that the vertical component of the compensatory continued eruption of the incisors had been insufficient. The sagittal directions of eruption differed somewhat. The incisors showed a compensatory eruption in a backward direction, whereas the molars erupted vertically throughout the observation period.

Discussion

Eruption of the teeth is a protracted process which begins in early childhood and probably continues into adulthood. There seems to be no general agreement on the terminology for the various phases of this process. Commonly, the term eruption is used for the developmental process that brings the tooth into its position of occlusion above the bone and gingiva. The emergence of a tooth through the oral mucosa is sometimes also known as eruption, but this event covers only a brief moment in life. The

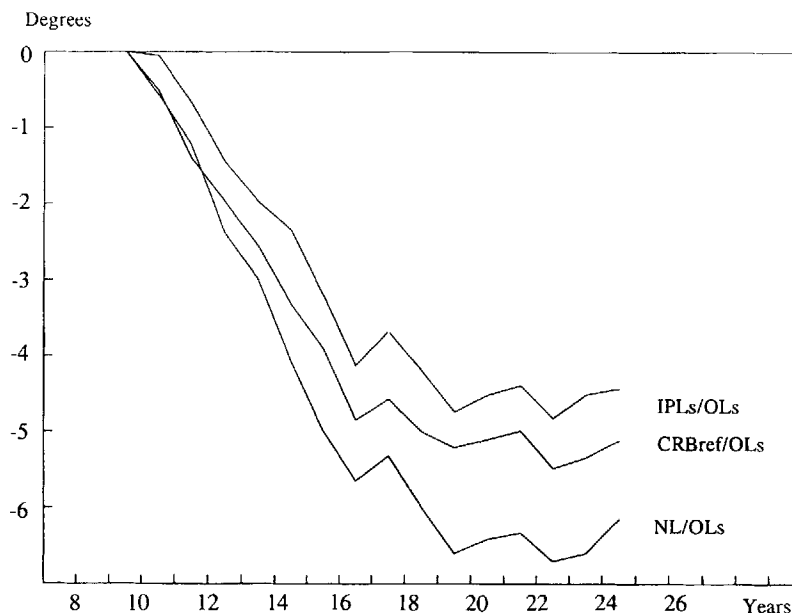


Figure 6 *Occlusal plane changes.* The average cumulative change in inclination of the maxillary occlusal plane, OLs, in relation to the implant line, IPLs, the anterior cranial base, CRBref, and the palatal plane, NL. The age scale indicates age-interval midpoints. The inclination at 10 years was arbitrarily set to zero. Negative values indicate a less steep inclination.

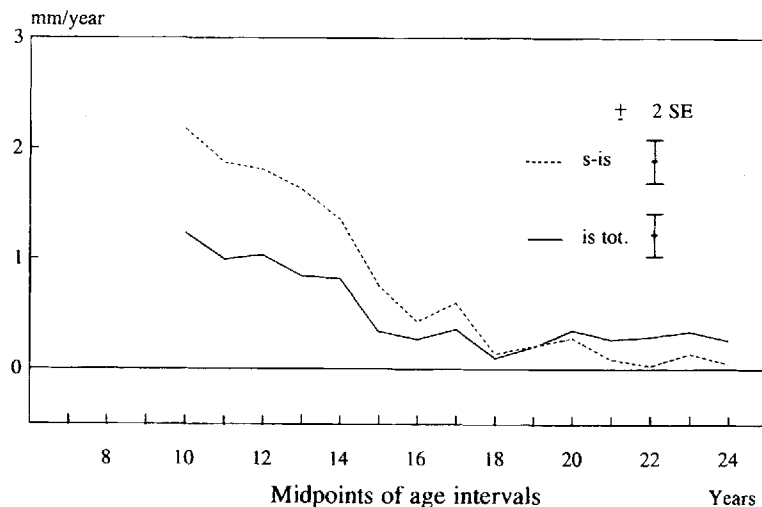


Figure 7 *Velocity, incisors.* Average velocity of continued eruption (is tot.) and translocation (s-is) of maxillary incisors. The velocities were calculated from the horizontal and vertical components of the annual positional changes.

term 'drift' of a tooth has been used to describe the vertical and horizontal movements of the tooth and its socket that subsequently occur in order to keep pace as the maxilla and mandible enlarge and develop (Enlow, 1990, p. 132), but the term 'drift' is also being used to describe the composite process of deposition and resorp-

tion which results in relocation of an area of a bone (Enlow, 1990, p. 26). Therefore, in the present study, we have preferred to use the term continued eruption to designate the eruptive movements of the teeth that occur after emergence into occlusion.

The terms remodelling, relocation, drift and

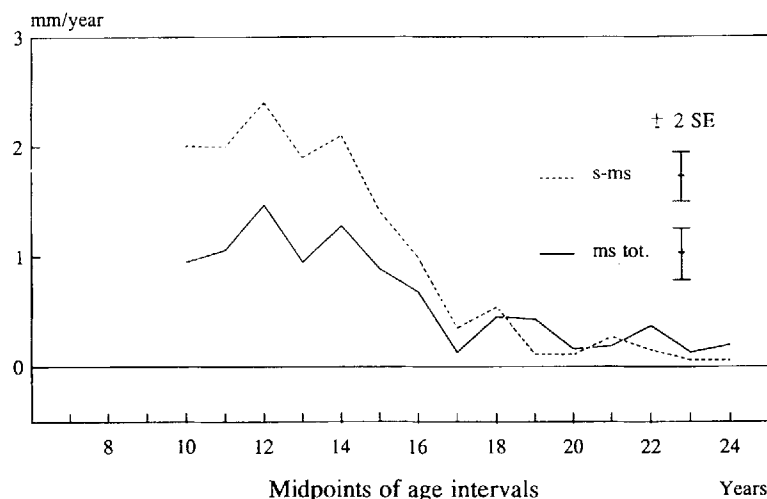


Figure 8 *Velocity, molars.* Average velocity of continued eruption (ms tot.) and translocation (s-ms) of maxillary first molars. The velocities were calculated from the horizontal and vertical components of the annual positional changes. Notice peak velocity at 12 years of age.

displacement are used to describe growth changes in the craniofacial skeleton (Enlow, 1990), but there is no term for the combined effects of eruption of the teeth and displacement of the maxilla. This is of relevance in analysis of the eruption of maxillary teeth, because it is customary to relate maxillary dento-alveolar changes to the cranial base in order to avoid the difficulties of maxillary superimposition. Therefore, the term translocation was introduced to designate the combined effect of the growth displacement of the maxillary body and the eruptive movement of a tooth or the relocation of a reference point due to surface remodelling.

In order to ensure that full emergence of the maxillary central incisors had occurred, the lower age limit in this study was set to 9 years. Many of the girls had received orthodontic treatment followed by retention for a period of time during the course of observation. Since the main aim of the study was to obtain data for eruptive movements of the teeth uninfluenced by orthodontic treatment, initial size differences as well as changes during periods of treatment and retention were eliminated by a specially developed computerized technique which (i) excluded increments during periods of orthodontic treatment and retention from the calculations of averages and (ii) constructed average curves by cumulating the averages of

the remaining available individual annual increments.

The average vertical component of continued eruption of the maxillary central incisors from 9–25 years of age, as assessed from the cumulated mean annual increments, was about 6 mm, and the corresponding amount of translocation was about 9.5 mm. The difference of 3.5 mm may be accounted for by the average sutural lowering of the anterior part of the maxilla (ia) in the same period (Iseri and Solow, 1990). For the molars, the vertical component of the continued eruption was about 8 mm and the corresponding amount of translocation about 12.5 mm, the 4.5 mm difference being accounted for by the somewhat larger lowering of the posterior part of the maxilla (ip).

The variability in amount and direction of continued eruption was large. Two factors of major importance for this variability were identified in the present study: (i) the dependency of the rate of eruption upon the general maturity of the subjects. This has previously been demonstrated by Siersbæk-Nielsen (1971) for maxillary incisors in a sample of eight boys, and was evidenced in the present study by the average velocity curves for the continued eruption of the molars which showed a peak at the time of maximum pubertal sutural growth (Iseri and Solow, 1990); (ii) the dependency of rate and direction of continued eruption upon the

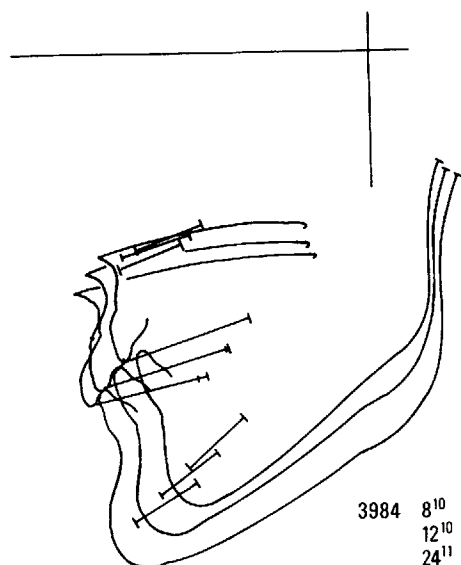


Figure 9 Facial growth, case 3984. Facial growth tracings at three age stages superimposed on stable structures in the anterior cranial base. Ages given in years and months. Notice large forward mandibular growth.

general pattern of growth of the facial skeleton and, in particular, the changes in sagittal and vertical jaw relationships. This was demonstrated by the paths of continued eruption for cases 3220 and 3984 and the corresponding tracings of facial growth in these subject, and may be seen as illustrations of the dento-alveolar compensatory mechanism by which the teeth and alveolar processes during growth adapt to changes in sagittal, vertical and transversal jaw relationships (Solow, 1966, 1980).

A relationship between the rates of maxillary and mandibular growth and general skeletal maturation is well established. It is possible, therefore, that the first of the above factors, the relation between eruption rate and skeletal maturation, is a consequence of the second factor, the adaptation of the eruptive movements to the changes in jaw relationships.

The total cumulated amount of eruption was larger for the molars than for the incisors, so that the inclination of the upper occlusal plane was reduced. This was in agreement with the findings of Björk and Skieller (1972) in a sample of boys and girls examined before and after peak pubertal growth, and can be related to the fact that during growth the mandible on average rotates more forwards than the maxilla,

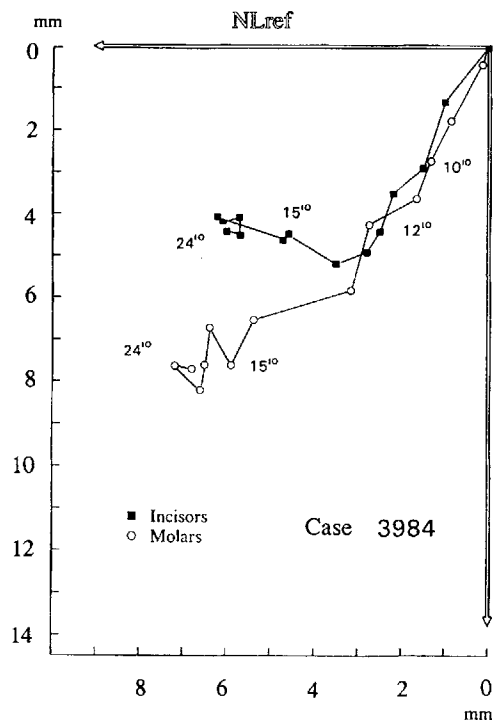


Figure 10 Continued eruption, case 3984. Individual paths of continued eruption of maxillary incisors and molars in case 3984. Superimposition on IPLs, registered on ia for is, and on ip for ms. Ages given in years and months. The points of origin of the two curves have been superimposed to facilitate comparison. Notice the directions of continued eruption, adapting the maxillary dental arch to the change in sagittal jaw relations: After the age of 12 years 10 months the incisors tip forwards as the maxillary forward sutural growth displacement decelerates while the forward mandibular growth continues (Fig. 9).

thus usually triggering a compensatory eruptive response in the molar region.

After the age of 16, there was no systematic change in the average inclination of the occlusal plane to the maxillary implant line. Thus, after this age, which corresponds to the termination of the pubertal growth spurt in girls, the average amounts of eruption of incisors and molars were of the same magnitude. This is in agreement with the findings of Sarnäs and Solow (1980), that the average amounts of late continued eruption were of the same magnitude for incisors and molars, about 1 mm, in samples of young adult males and females studied longitudinally from 21 to 26 years of age.

The changes in inclination of the occlusal plane were somewhat larger in relation to the

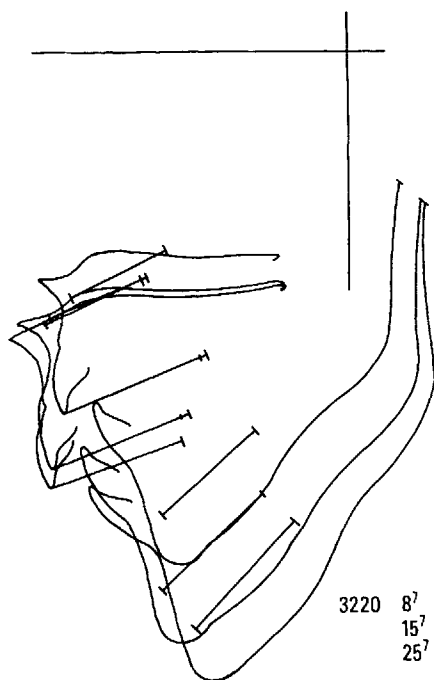


Figure 11 Facial growth, case 3220. Facial growth tracings at three age stages superimposed on structures in the anterior cranial base. Ages given in years and months. Notice that the sutural growth displacement of the maxilla had almost terminated by the age of 15 years 7 months, while the backward mandibular growth rotation continued.

anterior cranial base than in relation to the implant line. This is due to the fact that the maxillary body, and thus the implant line, rotates somewhat in relation to the anterior cranial base (Iseri and Solow, 1995), i.e. the average changes in CRBref/OLs represent the combined effects of the eruption of the maxillary teeth and the forward rotation of the maxilla. The changes in inclination of the occlusal plane in relation to the palatal plane, NL/OLs, were much larger than in relation to the implant line. This is due to the differential relocation of the reference points sp and pm caused by the remodelling of the nasal floor (Iseri and Solow, 1995). This discrepancy is of considerable clinical importance, and should be taken into account in assessment of long periods of growth and treatment changes of the maxillary occlusal plane.

Osseointegrated techniques using titanium implants have been in clinical use for many years (Brånemark *et al.*, 1977) and osseointegrated implants have also been used in some

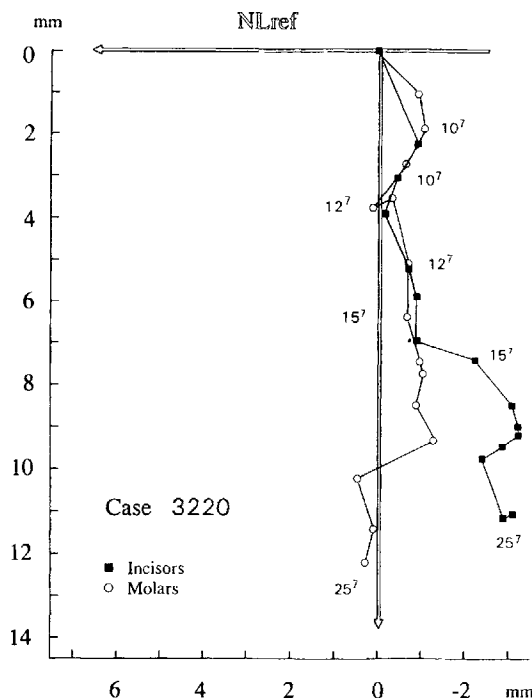


Figure 12 Continued eruption, case 3220. Individual paths of continued eruption of maxillary incisors and molars in case 3220. Superimposition on IPLs, registered on ia for is, and on ip for ms. Ages given in years and months. The points of origin of the two curves have been superimposed to facilitate comparison. Notice the large amount of downward and backward continued eruption of the maxillary incisors, adapting the maxillary dental arch to the change in sagittal and vertical jaw relations in this skeletal growth pattern (Fig. 11).

orthodontic situations. It is important to realize, however, that once an implant with an artificial tooth is osseointegrated in a growing alveolus, there will be no further alveolar growth at the implant site, whereas the growth in adjacent regions continues in all three dimensions. Artificial teeth on osseointegrated fixtures in growing individuals therefore can end up in infra-occlusion because of the continued eruption of the neighbouring teeth. In the present study, the peak velocity of continued eruption was followed by a decreasing velocity up to the age of about 18 years. Moreover, studies of late facial growth have shown continued eruption of the teeth into the third, and possibly the fourth decades of life (Forsberg, 1979; Forsberg *et al.*, 1991; Sarnäs and Solow, 1980). Thus, the use of osseointegrated implants with artificial teeth in childhood, adolescence, and early

adulthood should not be recommended neither in anterior nor posterior dento-alveolar segments unless special provision is made for later revision or replacement of the artificial teeth to compensate for the lack of continued eruption.

Address for correspondence

Professor Beni Solow
Department of Orthodontics,
School of Dentistry
Nørre Allé 20
DK-2200 Copenhagen N, Denmark

Acknowledgement

This study was supported by a TUBITAK grant from the Scientific and Technical Research Council of Turkey.

References

- Ainamo J, Talari A 1976a The increase with age of the width of attached gingiva. *Journal of Periodontal Research* 11: 182–188
- Ainamo J, Talari A 1976b Eruptive movements of teeth in human adults. In: Poole D F G, Stack M V (eds.) *The eruption and occlusion of teeth*. Butterworths, London: pp. 97–107
- Baer M J 1956 Dimensional changes in the human head and face in the third decade of life. *American Journal of Physical Anthropology* 14: 557–575
- Behrents R G 1985a Growth in the aging craniofacial skeleton. Monograph 17, Craniofacial Growth Series. Center for Human Growth and Development, The University of Michigan, Ann Arbor: pp. 1–145
- Behrents R G 1985b An atlas of growth in the aging craniofacial skeleton. Monograph 18, Craniofacial Growth Series. Center for Human Growth and Development, The University of Michigan, Ann Arbor: pp. 1–160
- Björk A 1955 Facial growth in man, studied with the aid of metallic implants. *Acta Odontologica Scandinavica* 13: 9–34
- Björk A 1968 The use of metallic implants in the study of facial growth in children: method and application. *American Journal of Physical Anthropology* 29: 243–254
- Björk A, Skieller V 1972 Facial development and tooth eruption. *American Journal of Orthodontics* 62: 339–383
- Björk A, Skieller V 1977 Growth of the maxilla in three dimensions as revealed radiographically by the implant method. *British Journal of Orthodontics* 4: 53–64
- Björk A, Skieller V 1983 Normal and abnormal growth of the mandible. *European Journal of Orthodontics* 5: 1–46
- Brånemark P-I, Hansson B O, Adell R, Breine U, Lindström J, Hallen O, Öhman A 1977 Osseointegrated implants in the treatment of the edentulous jaw. Experience from a 10-year period. *Scandinavian Journal of Plastic and Reconstructive Surgery* 16 (Suppl.)
- Burke P H 1954 Eruption analysis. *Transaction of the European Orthodontic Society*, pp. 343–354
- Carlsson H 1944 Studies on the rate and amount of eruption of certain human teeth. *American Journal of Orthodontia, Orthodontics and Dentistry for Children* 30: 575–588
- Enlow D H 1990 Facial growth. 3rd edn. W. B. Saunders, Philadelphia, USA
- Forsberg C M 1979 Facial morphology and ageing: a longitudinal cephalometric investigation of young adults. *European Journal of Orthodontics* 1: 15–23
- Forsberg C M, Eliasson S, Westergren H 1991 Face height and tooth eruption in adults. A 20-year follow-up investigation. *European Journal of Orthodontics* 13: 249–254
- Gray J B, Steen M E, King G J, Clark A E 1983 Studies on the efficacy of implants as orthodontic anchorage. *American Journal of Orthodontics* 83: 311–317
- Haanaes H R, Stenvik A, Beyer-Olsen E S, Tryti T, Faehn O 1991 The efficacy of two-stage titanium implants as orthodontic anchorage in the preprosthetic correction of third molars in adults, a report of three cases. *European Journal of Orthodontics* 13: 287–292
- Helwig J T, Council K A 1979 SAS User's Guide. SAS Institute Inc., Raleigh, North Carolina, USA
- Iseri H, Solow B 1990 Growth displacement of the maxilla in girls studied by the implant method. *European Journal of Orthodontics* 12: 389–398
- Iseri H, Solow B 1995 Average remodelling of the maxillary base and the orbital floor in girls from 8 to 25 years. An implant study. *American Journal of Orthodontics and Dentofacial Orthopedics* 107: 48–57
- Mazeland G R J 1980 The mucogingival complex in relation to alveolar process height and lower anterior face height. *Journal of Periodontal Research* 15: 345–352
- Murphy T 1959 Compensatory mechanisms in facial height adjustment to functional attrition. *Australian Dental Journal* 4: 312–323
- Ödman J, Gröndahl K, Lekholm U, Thilander B 1991 The effect of osseointegrated implants on the dento-alveolar development. A clinical and radiographic study in growing pigs. *European Journal of Orthodontics* 13: 279–286
- Ödman J, Lekholm U, Jemt T, Brånemark P-I, Thilander B 1988 Osseointegrated titanium implants—a new approach in orthodontic treatment. *European Journal of Orthodontics* 10: 98–104
- Ödman J, Lekholm U, Jemt T, Thilander B 1994 Osseointegrated implants as orthodontic anchorage in the treatment of partially edentulous adult patients. *European Journal of Orthodontics* 16: 187–202
- Roberts W E, Helm F R, Marshall K J, Gangloff R K 1989 Rigid endosseous implants for orthodontic and orthopedic anchorage. *Angle Orthodontist* 59: 247–256
- Sarnäs K-V, Solow B 1980 Early adult changes in the skeletal and soft-tissue profile. *European Journal of Orthodontics* 2: 1–12
- Schumacher D B, El Hadary M S 1960 Roentgenographic study of eruption. *Journal of the American Dental Association* 61: 535–541

- Siersbæk-Nielsen S 1971 Rate of eruption of central incisors at puberty: an implant study on eight boys. *Danish Dental Journal* 75: 1288–1295
- Solow B 1966 The pattern of craniofacial associations. A morphological and methodological correlation and factor analysis study on young male adults. *Acta Odontologica Scandinavica* 24 (Suppl. 46): 1–174
- Solow B 1980 The dentoalveolar compensatory mechanism. *British Journal of Orthodontics* 7: 145–161
- Tallgren A 1957 Changes in adult face height due to ageing, wear and loss of teeth and prosthetic treatment. *Acta Odontologica Scandinavica* 15 (Suppl. 24)
- Tallgren A, Solow B 1991 Age differences in adult dentoalveolar heights. *European Journal of Orthodontics* 13: 149–156
- Thilander B, Ödman J, Gröndahl K, Lekholm, U 1992 Aspects on osseointegrated implants inserted in growing jaws. A biometric and radiographic study in the young pig. *European Journal of Orthodontics* 14: 99–109
- Thilander B, Ödman J, Gröndahl K, Friberg G 1994 Osseointegrated implants in adolescents. An alternative in replacing missing teeth? *European Journal of Orthodontics* 16: 84–95
- Thompson J L Jr, Kendrick G S 1964 Changes in the vertical dimensions of the human male skull during the third and fourth decades of life. *Anatomical Record* 150: 209–213
- Turley P K, Kean C, Schur J, Stefanac J, Gray J, Hennes J, Poon L C 1988 Orthodontic force application to titanium endosseous implants. *Angle Orthodontist* 58: 151–162